

# Management of Sympathetic Ophthalmia with the Fluocinolone Acetonide Implant

Vinit B. Mahajan, MD, PhD,<sup>1</sup> Karen M. Gehrs, MD,<sup>1</sup> Debra A. Goldstein, MD,<sup>2</sup> David H. Fischer, MD,<sup>3</sup> Juan S. Lopez, MD,<sup>4</sup> James C. Folk, MD<sup>1</sup>

**Objective:** We examined whether implantation of the fluocinolone acetonide (Retisert) implant achieved control of inflammation and a reduced need for oral corticosteroids or immunosuppressives in patients with sympathetic ophthalmia (SO).

**Design:** Retrospective, noncomparative case series.

**Participants:** Eight patients with active SO.

**Methods:** The results of fluocinolone acetonide implantation in 8 patients with active SO were studied with a follow-up period of 6 months to 2 years.

**Main Outcome Measures:** Presence or absence of intraocular inflammation, visual acuity, intraocular pressure, need for further surgery, and the need for additional use of oral or locally injected corticosteroids and/or immunosuppressives.

**Results:** All patients demonstrated a significant reduction in the systemic medication required to maintain control of inflammation. Two patients had recurrent inflammatory episodes requiring the resumption of an oral immunosuppressive. Vision improved or was stabilized in all 8 patients.

**Conclusions:** The fluocinolone acetonide implant provides inflammatory control and reduces the dependence on systemic immunosuppression in patients with SO.

**Financial Disclosure(s):** The authors have no commercial or proprietary interests in any material discussed in this article. *Ophthalmology* 2009;116:552–557 © 2009 by the American Academy of Ophthalmology.



Sympathetic ophthalmia (SO) is a rare but devastating complication of ocular surgery or penetrating trauma.<sup>1</sup> It is believed that the exposure of a uveal self-antigen in an operated or traumatized eye incites an autoimmune panuveitis.<sup>2,3</sup> Treatment often requires corticosteroids and systemic immunosuppression to control intraocular inflammation and maintain vision. Inflammatory control is usually initiated with high-dose oral prednisone and maintained with the addition of immunosuppressives such as cyclosporine, azathioprine, or mycophenolate mofetil.<sup>1</sup> Although these agents have significant systemic morbidity, the treatment of SO often must be continued for years to prevent blindness.

Cell-mediated autoimmunity is restricted to the eye in SO, thus, local therapy such as periocular or intraocular corticosteroid injections has emerged as an important therapeutic adjuncts that can reduce the need for systemic therapy.<sup>4,5</sup> These local methods are limited, however, by the need for frequent repeat injections because of the chronic nature of the disease.

The fluocinolone acetonide implant (Retisert, Bausch & Lomb, Rochester, NY), provides continuous release of intraocular corticosteroid for approximately 2.5 years. It is surgically implanted through the pars plana into the vitreous and sutured to the sclera. A large, multicenter clinical trial of noninfectious posterior uveitis demonstrated this device was effective in controlling intraocular inflammation and re-

ducing the need for systemic and local therapy.<sup>6</sup> We describe our combined experiences using this drug delivery system in 8 patients with active SO.

## Methods

A retrospective case series was assembled from 5 SO patients from The University of Iowa, 1 patient from the Wills Eye Institute, and 2 patients from the Bausch & Lomb clinical trial dataset. Clinical examinations for preoperative and postoperative examinations were performed by vitreoretinal or uveitis specialists (authors). The diagnosis of SO was made because all patients had a history of trauma or surgery to the fellow eye; all patients had the presence of small, yellow, chorioretinal inflammatory lesions or scars throughout the fundus; all patients had inflammation in the aqueous and vitreous; all patients had no other evidence of an infection; all patients had negative skin tests for the tuberculin purified protein derivative; all patients had no serologic or clinical evidence of sarcoidosis; and typical findings of SO were seen in the 5 enucleated eyes of 5 patients.

Patients were treated with oral prednisone, sub-Tenon's triamcinolone acetonide, intravitreal triamcinolone acetonide, and a variety of oral immunosuppressives under the direction of 5 physicians. No standard treatment regimen was used. Treatment failures were defined as incomplete inflammatory control or intolerable side effects from a given treatment regimen. The indication for surgery was likewise failure of systemic immunosuppression to control inflammation or intolerable side-effects. The approval of the Institutional Review Board for Hu-

Table 1. Demographic Data and Operative History

Patient No.	Age	Gender	Inciting Eye Surgery/Trauma (mos before diagnosis)	Sympathizing Eye Surgery (mos after diagnosis)
1	52	M	(22) Scleral buckle (9) Vitrectomy (7) Vitrectomy	(0, 2, 3) Intravitreal triamcinolone acetonide (7) Trabeculectomy (13) Cataract extraction with intraocular lens (43) Fluocinolone acetonide implant
2	78	F	(1) Open globe (1) Vitrectomy	(0,6) Intravitreal triamcinolone acetonide (8) Cataract extraction with intraocular lens (8) Fluocinolone acetonide implant (21) Trabeculectomy
3	72	M	(6) Vitrectomy (6) Vitrectomy, CE/IOL	(18, 24, 29, 32, 65, 66, 82) Intravitreal triamcinolone acetonide (18) Cataract extraction with intraocular lens (35) Ahmed valve (70) Fluocinolone acetonide implant
4	73	F	(36) Cataract (20) Penetrating keratoplasty	(9, 12, 19, 20, 30, 34) Intravitreal triamcinolone acetonide (10) Trabeculectomy (36) Cataract extraction with intraocular lens (43, 46) DLEK (46) Fluocinolone acetonide implant
5	62	M	(36) Globe laceration (35) Vitrectomy (34) Vitrectomy (32) Vitrectomy + silicon oil	(12) Cataract extraction with intraocular lens (18) Intravitreal triamcinolone acetonide (45) Fluocinolone acetonide implant
6	39	M	(48) Vitrectomy (48) Vitrectomy (48) Vitrectomy	(24) Vitrectomy (24) Cataract extraction with intraocular lens (36) Thermal laser (46) Periocular Triamcinolone (60) Fluocinolone acetonide implant
7	23	M	(1) Globe laceration	(165) Iridotomy (166) Cataract extraction with intraocular lens (197, 198, 202) YAG capsulotomy (198, 199, 203, 205, 206) Intravitreal triamcinolone acetonide (207) Fluocinolone acetonide implant (218) Vitrectomy + silicone oil
8	38	M	(1) Bilateral globe laceration	(11) CE/IOL(multiple) Sub-Tenon's triamcinolone (60) Fluocinolone acetonide implant

CE/IOL = cataract extraction with intraocular lens placement; DLEK = deep lamellar endothelial keratoplasty; F = female; M = male; YAG = yttrium aluminium garnet.

man Subjects Research was obtained at all institutes to review the data and publish this case series. After informed patient consent was obtained, surgical implantation was performed as previously described.<sup>6</sup> All visual acuities are best-corrected Snellen acuities. No standardized refractions or visual acuity measurements were used. A recurrence of inflammation after implantation was diagnosed by inflammatory cells in the aqueous or vitreous or fibrin in the vitreous and was usually accompanied by blurred vision.

## Results

Eight patients with SO underwent surgical implantation of the fluocinolone acetonide device (Tables 1 and 2). Seven received the 0.59-mg dose, but 1 subject (patient 7) received the 2.1-mg dose as part of a randomized, double-masked, controlled clinical study. Postoperative follow-up ranged from 3 months to 2 years. The inciting event was trauma in 4 patients, retinal detachment surgery in 3, and multiple anterior segment surgeries followed by retinal detachment surgery in 1. All patients had a history of multiple eye surgeries and developed SO within a range of 2 months to 3 years after their last surgery (Table 1).

Oral immunosuppressive medications that were used before surgery included up to 80 mg prednisone (7 of 8 subjects), 1000 to 2000 mg/d of mycophenolate mofetil (3 of 8 subjects), 100 to 200 mg/d azathioprine (3 of 8 subjects), 200 to 375 mg cyclosporine (1 of 8), and chlorambucil (1 of 8; Table 1). After device implantation, 2 patients have not had recurrent inflammation for over 2 years, and the most recent patient has been quiet for over 6 months. There were 5 patients with recurrent inflammation. Two of these only required brief treatment with topical prednisolone acetate. One patient had mild inflammation in the vitreous with vision loss 1 year after surgery; the inflammation was controlled with injections of intravitreal triamcinolone and 15 mg/wk oral methotrexate. In the second patient, ocular inflammation recurred 2 months after device implantation and simultaneous cataract surgery. She was restarted on 200 mg azathioprine, which in combination with the implant, has resulted in control of the inflammation. All 8 patients achieved a significant reduction in the dose and number of systemic medications needed for inflammatory control, and 5 patients were able to completely discontinue their systemic immunosuppressive medications.

Five of the 8 patients underwent enucleation of the inciting eye at the time SO was diagnosed. Pathologic examination of the tissues confirmed SO all cases. Advanced chorioretinal scarring

Table 2. Vision and Inflammation

Patient	Visual Acuity—Best Corrected Snellen					Oral Prednisone and Immunosuppression		Recurrent Episodes
	Preop	3 mo	6 mo	12 mo	24 mo	Preoperative	Postoperative	
1	20/20	20/20	20/20	20/20	20/20	Prednisone MMF Cyclosporine	None	0
2	20/80	20/125	20/80	20/80	20/80	Prednisone MMF	MMF	1
3	HM	HM	HM	HM	HM	Prednisone Cyclosporine Azathioprine	Azathioprine	1
4	HM	20/200	20/60	20/80	20/160	Prednisone Azathioprine	Azathioprine	1
5	20/25	20/25	20/25	20/25	NA	Prednisone MMF Chlorambucil Azathioprine	Azathioprine taper	0
6	20/200	20/80	20/80	NA	NA	Prednisone	None	0
7	20/20	20/15	20/20	20/20	20/20	None	None	0
8	20/100	20/30	20/30	20/30	20/25	Prednisone	None	2

HM = hand motion; MMF = mycophenolate mofetil; NA = not available.

with poor vision was present preoperatively in the fellow eye before implantation of the device in 2 patients (cases 2 and 3). Nevertheless, visual acuity was stabilized in 7 patients after device implantation (Table 2). Visual acuity decline in 1 patient (case 4) was due to recent corneal graft failure and an epiretinal membrane causing chronic cystic changes in the macula, but the eye remains quiet.

Seven patients were pseudophakic before surgery, and the remaining patient elected simultaneous phacoemulsification and lens implantation at the time of device placement. Two patients had undergone trabeculectomies, and 1 had an Ahmed valve for steroid-induced glaucoma before device implantation. A 4th patient required trabeculectomy 1 year after implant placement. The remaining 4 patients, including the one who was implanted 6 months ago, have not required antiglaucoma medication or surgical intervention. The clinical courses of the patients are described below.

### Patient 1

The patient underwent scleral buckle surgery for a retinal detachment followed by 3 vitrectomies and silicone oil for recurrent detachment and proliferative vitreoretinopathy in his right eye (Table 1). He sought a second opinion for his poor visual outcome as well as difficulty reading with his good left eye. On our examination, the retina in the right eye was attached and there were no signs of inflammation. In the left eye, however, punctate white spots and pigmentary changes were observed. Figure 1 (available online at <http://aaajournal.org>). The left eye had a visual acuity of 20/25. There was no vitreous cell, choroidal thickening on echography, or leakage on fluorescein angiography at this time. Within 2 weeks, however, he developed vitreous cells and punctate yellow white spots in both eyes and leakage on his fluorescein angiogram.

Oral prednisone at a dose of 80 mg/d was started along with topical prednisolone acetate drops. A few weeks later, the patient elected to undergo enucleation of the inciting right eye, which had only light perception vision. The pathology report confirmed SO. The inflammation recurred during the tapering of his oral pred-

nison. He was given azathioprine, 100 mg/d, and a periocular steroid injection of 40 mg triamcinolone acetonide. After 4 months, he began to lose vision and had elevated intraocular pressure (IOP). He was switched from azathioprine to 375 mg/d cyclosporine and his oral prednisone dose was raised from 12.5 to 60 mg.

Medical management of steroid response glaucoma failed, and he required a trabeculectomy 3 months later. He developed a cataract and underwent surgery that included cataract removal, intraocular lens implantation, and intraocular steroid injection of 4 mg triamcinolone acetonide 7 months later. His visual acuity was subsequently measured to be 20/20 and his prednisone was tapered to less than 10 mg.

Over the next 2 years, he experienced episodes of recurrent inflammation, macular edema, and visual field loss. This was treated with 2 intravitreal injections of 4 mg triamcinolone acetonide, 1 g oral mycophenolate mofetil twice a day, and increasing his oral prednisone dose up to 60 mg. It was not possible to taper his prednisone dose below 20 mg/d, even with the mycophenolate mofetil, so a fluocinolone acetonide implant surgery was performed. Three months after surgery, his immunosuppressive medications were discontinued. The prednisone was slowly decreased from 20 mg/d, until it was discontinued 6 months after implantation. His left eye has remained free of inflammation for over 2 years, and he has 20/20 vision. His trabeculectomy continues to function and the IOP is well controlled. Visual fields have remained stable for 2 years.

### Patient 2

A 76-year old woman suffered a globe laceration of the left eye that was repaired with 2 vitrectomies, but her vision remained no light perception (Table 1). Within 1 month after the injury, she developed a panuveitis in the right eye consistent with SO. The diagnosis of SO was confirmed 8 months later by pathology after enucleation of her left eye. The inflammation was controlled with injections of 4 mg intravitreal triamcinolone acetonide and oral medication that included 1 g twice a day of mycophenolate mofetil and up to 40 mg/d prednisone.

Even with the mycophenolate mofetil, the prednisone could not be tapered to below 20 mg/d, which was not tolerated by the patient. She elected to undergo fluocinolone acetonide implant in the right eye. Both her mycophenolate mofetil and prednisone were tapered and discontinued by 3 months after implantation. She developed mild recurrent anterior and vitreous cell and was restarted on mycophenolate mofetil 2 g/d without any oral prednisone. A trabeculectomy was performed 21 months after the implantation for elevated IOP as high as 32 mmHg. Her vision remains stable with the combination of the fluocinolone implant and mycophenolate mofetil at a dose of 1 g orally twice a day.

### Patient 3

A 72-year-old man developed panuveitis in both eyes after 2 vitrectomies and cataract surgery for recurrent retinal detachments with proliferative vitreoretinopathy in the right eye (Table 1). At diagnosis, the vision was no light perception in the right eye and hand motions in the left. There was no view of the posterior pole in the right eye. The left eye showed numerous chorioretinal nodules along with cells in the anterior chamber and vitreous. The right eye was enucleated and pathology examination confirmed SO.

The patient was treated with 150 mg azathioprine and up to 60 mg of prednisone for 4 months, but he developed nausea and hematomas in the joints and skin from the medications and along with Ehlers–Danlos syndrome. He was placed on 2 g mycophenolate mofetil and his prednisone was tapered to 5 mg and azathioprine to 50 mg. His visual acuity stabilized at 20/200.

A recurrent inflammatory episode with anterior chamber and vitreous cell was managed with intravitreal 4 mg triamcinolone acetonide injections and by replacing the mycophenolate mofetil with 250 mg/dd cyclosporine for the next year. He developed hypertension and elevated creatinine levels whenever the cyclosporine dose was increased. The cyclosporine was discontinued. The patient did not tolerate a brief treatment course of oral cyclophosphamide. His primary care physician expressed concern over any immunosuppressive use because of hypertension and bleeding into joints caused by their use and the Ehlers–Danlos syndrome. Several episodes of recurrent vitreous cell were treated with 4 to 8 mg triamcinolone acetonide intravitreal injections, but his vision slowly deteriorated to hand motions. He developed steroid-induced glaucoma with IOP as high as 40 mmHg. Surgical implantation of an Ahmed glaucoma valve was performed. Because of the frequent need for intravitreal triamcinolone acetonide injections, he elected to undergo fluocinolone acetonide implantation. One year later, a single episode of vitreous cells was controlled with an injection of intravitreal 4 mg triamcinolone acetonide and placing the patient on 15 mg of methotrexate weekly, which has been well tolerated. He has remained free of inflammation for another year with the fluocinolone acetonide implant and oral methotrexate.

### Patient 4

A 73-year-old woman developed SO in the right eye 3 years after a complicated cataract surgery in the left eye that was followed 16 months later by penetrating keratoplasty for bullous keratopathy (Table 1). One year after the second procedure, she presented with a total retinal detachment and light perception vision in the left eye, but deferred surgical repair. Five months after that, she developed a panuveitis in the right eye with a decrease in vision from 20/25 to 20/300. Her vision in the left eye at this time was no light perception. The clinical diagnosis of SO was confirmed 1 month later by pathology after enucleation of the left eye.

Over the following 4 years, her inflammation was controlled with 200 mg/d azathioprine, up to 40 mg of oral prednisone, topical prednisolone acetate, and 4 mg intravitreal triamcinolone

acetonide injections; her vision remained in the 20/80 range. She then underwent cataract surgery and later trabeculectomy in the right eye for steroid-induced glaucoma. During this period, she suffered further decline in vision to hand motions owing to recurrent cystoid macular edema, an epiretinal membrane, and pseudophakic bullous keratopathy. She underwent deep lamellar endothelial keratoplasty, which failed owing to graft folding. A second deep lamellar endothelial keratoplasty procedure was combined with placement of the fluocinolone acetonide implant to help treat the cystoid macular edema and possibly improve graft survival. Although her 6-month postoperative vision improved to 20/60, recurrent graft failure reduced her acuity to 20/160. Her eye has remained free of inflammation.

### Patient 5

A 62-year-old man developed SO in the right eye 19 months after a globe laceration and retinal detachment in the left eye that was repaired with 3 vitrectomies and silicone oil (Table 1). His visual acuities were 20/25 in the right eye and no light perception in the left eye. Pathologic examination of the enucleated left eye showed SO.

Oral mycophenolate mofetil 200 mg/d was given, but his oral prednisone dose could not be decreased below 60 mg/d. After 1 year of therapy, he developed osteoporosis, hypertension, renal lithiasis, and elevated blood sugars. After presentation to our institute, he was started on 200 mg/d azathioprine and the oral prednisone was tapered to 15 mg after 5 months. When his prednisone was reduced to 10 mg, however, he suffered recurrent inflammation with anterior and vitreous cell and lost 1 line of vision. He elected to undergo fluocinolone acetonide implantation. His prednisone was reduced to below 10 mg within 1 month, and his azathioprine was tapered to 150 mg. He underwent a trabeculectomy 10 months after implantation, and his vision remained 20/25 at the 1-year postoperative visit.

### Patient 6

A 39-year-old man underwent a scleral buckle procedure and 2 vitrectomies over 5 months in his right eye to repair a recurrent retinal detachment (Table 1). Two years later, he was referred to the Wills Eye Institute with a diagnosis of SO. His visual acuity was no light perception in the right eye and 20/30 in the left eye. He was found to have panuveitis in the left eye with chorioretinal scarring consistent with Dalen–Fuchs nodules. He was placed initially on 80 mg oral prednisone. He remained stable for 2 years on 20 mg prednisone, and then underwent a cataract extraction, lens implantation, intraocular triamcinolone acetonide 4 mg, and vitrectomy for vitreous debris. His visual acuity improved to 20/25, but 3 months afterward he developed increased inflammation that was controlled with 40 mg of oral prednisone. One year later, he noticed metamorphopsia and showed the presence of a peripapillary choroidal neovascular membrane. He underwent thermal laser procedures twice, but suffered recurrent inflammation and retinal edema. After multiple triamcinolone acetonide injections, he developed a new subfoveal choroidal neovascular membrane. He then elected to receive a series of bevacizumab 1.25 mg injections, but his vision continued to deteriorate as low as 20/200 owing to an active membrane, subretinal fluid, and persistent inflammation. The patient was still on 20 mg prednisone and had developed osteoporosis from chronic oral prednisone. He elected to have a fluocinolone acetonide implant. Within 3 months, the choroidal neovascular membrane regressed, there was no inflammation, his oral medication was steadily tapered from 20 mg/d, and his vision improved to 20/80. At his 6-month visit, he was on no prednisone or immunosuppressive medication and his vision was stable.



### Patient 7

A 23-year-old male patient suffered penetrating ocular trauma in the left eye and developed SO in the right eye (Table 1). The left eye vision was hand motions. A laboratory workup for infectious and rheumatologic uveitis was negative. Cataract surgery was performed on the right eye 14 years after his injury and his vision measured 20/20. He suffered recurrent bouts of recurrent inflammation that were managed with oral medication and repeated intravitreal triamcinolone. He enrolled in a randomized, double-masked, controlled clinical study and was implanted with a 2.1-mg fluocinolone acetonide implant. One month later his vision remained 20/20. A retinal detachment occurred 47 weeks after implantation, a possible complication of the implant surgery. This was repaired with vitrectomy and silicone oil. Although the patient maintained his 20/20 visual acuity, he was left with a persistent superior visual field defect. The eye has remained free of recurrent inflammatory episodes.

### Patient 8

A 38-year-old man with type 2 diabetes suffered an accident causing bilateral globe rupture (Table 1). After repair, his visual acuity was 20/70 in the right eye and 20/40 in the left eye. Two months later, he suffered a panuveitis in both eyes with decreased vision to count fingers in both eyes. A laboratory workup for infectious and rheumatologic uveitis was negative. He was treated with 100 mg oral prednisone. He was also given 150 mg cyclosporine, which he could not tolerate. He developed cataracts within 1 year. Cataract surgery was performed and his vision improved from count fingers in the right eye to 20/40 and count fingers in the left eye to 20/150. The prednisone could not be tapered, and recurrent bouts of inflammation were managed with 4 injections of 40-mg periocular triamcinolone acetonide in each eye for the next 4 years. After this unsuccessful management, he enrolled in a 3-year, randomized, double-masked, controlled clinical study testing the efficacy of the fluocinolone implant. He was implanted with an 0.59-mg fluocinolone acetonide implant in his right eye. His vision was 20/100 at the time of implantation. After the implant surgery, his visual acuity improved to approximately 20/25 and remained at that level during the 2-year follow-up period. Between implantation and the 2-year follow-up visit, the implanted eye suffered only 2 mild recurrences of anterior cell that were treated with topical prednisolone acetate. It did not develop increased IOP or need pressure-lowering drops after implantation. The fellow eye, which had not received an implant, had 6 recurrent episodes of anterior and vitreous cell in the same 2-year period, which were treated with combinations of periocular injections of triamcinolone acetonide 40 mg and topical prednisolone acetate.

## Discussion

Sympathetic ophthalmia is a difficult disease to treat because the inflammation is often severe and chronic and results in significant vision loss. Vision loss is usually due to cystoid macular edema, chorioretinal atrophy, or hypotony.<sup>7-9</sup> Oral prednisone is often an effective treatment. The problem is that often medium to high doses of prednisone must be used for prolonged periods to control the inflammation. This prolonged use results in osteoporosis, hypertension, muscle loss, and weakness. Some patients become anxious, depressed, or feel poorly on systemic steroids and do not wish to take them. Most patients eventually require an immunosuppressive agent.

The use of modern immunosuppressive agents have resulted in good control of inflammation and fairly good vision in most patients with SO.<sup>7-9</sup> We also have patients who have been well controlled on a variety of immunosuppressive agents. The patients in this report had disease that was difficult to control. They developed recurrent inflammation while on immunosuppressive agents or did not tolerate them. Perhaps the dose of the immunosuppressives could have been increased in a few patients, but it is difficult to wait for an effect while the patient has inflammation and is losing vision.

Local corticosteroid treatment is generally not effective long term. Triamcinolone acetonide can be given superior sub-Tenon's, but usually is insufficient by itself for control of the inflammation. Triamcinolone acetonide can also be given intravitreally but the chronic nature of SO necessitates repeated injections. Vision is often permanently lost with each recurrence of inflammation in SO, so episodic treatment is not ideal. In addition, either route of steroid dosing generally causes cataracts; approximately one third of patients develop steroid-induced glaucoma, which can be severe.

The fluocinolone acetonide implant delivers a continuous low dose of fluocinolone over a 2.5-year period. The implant has been shown to result in excellent control of non-infectious uveitis.<sup>6,10,11</sup> The total dose of fluocinolone acetonide in the implant is only 0.59 mg, so the fluocinolone acetonide implant does not cause any systemic complications. The 3-year trial results of 278 patients who had fluocinolone acetonide implants showed that 78% needed pressure-lowering drugs and 40% needed IOP-lowering surgery.<sup>11</sup> Because 60% of eyes did not need IOP-lowering surgery, we would not recommend routine glaucoma surgery at the time of implantation. During the 3-year follow-up, 93% of phakic implanted eyes underwent cataract extraction. Therefore, perhaps cataract surgery should be performed simultaneously with implantation. On the other hand, the presence of an implant does not interfere with later cataract surgery.

In our series, 3 patients gained vision, probably because of resolution of the inflammation and macular edema. The remaining patients were stabilized and none lost vision compared with their preoperative level. The preexisting vision loss in our patients was mainly attributable to chorioretinal atrophy and, in 1 case, cystic macular changes from an epiretinal membrane along with corneal edema. The results support the use of the fluocinolone implant in patients with SO. The conclusions have to be tempered, however, because of the retrospective nature of the study and the relatively few patients.

Jaffe<sup>12</sup> reported that some patients with uveitis remained quiet even after the targeted 2.5 to 3 years when the fluocinolone acetonide implant would be expected to be depleted. In our experience, SO is a chronic disease. We expect that reimplantation of a new fluocinolone acetonide implant will be needed to control inflammation every 2.5 years. Reimplantation for uveitis has been successful and the devices and medication seem to be well tolerated over 3 years of follow-up. The question is whether these patients should receive routine reimplantation of new devices after

2.5 years or should we wait until inflammation reoccurs? All but one of our patients has vision in only the implanted eye, so the decision to undergo surgery again is daunting. For now, we have elected to observe the patients carefully and reimplant at the first sign of recurrent inflammation.

The ultimate visual acuity in SO varies significantly with the severity of inflammation, chorioretinal scarring, and timing of treatment.<sup>13,14</sup> It is therefore unwise to delay treatment or continue a treatment that is ineffective. Once vision is lost to chorioretinal atrophy, it does not usually return. Our recommendation for initial treatment remains early and aggressive use of oral corticosteroids and other immunosuppressive agents. If the inflammation recurs, however, or the patient cannot tolerate the medications, we now consider earlier implantation of the fluocinolone implant than seen in this series of patients.

## References

- Damico FM, Kiss S, Young LH. Sympathetic ophthalmia. *Semin Ophthalmol* 2005;20:191–7.
- Gass JD. Sympathetic ophthalmia following vitrectomy. *Am J Ophthalmol* 1982;93:552–8.
- Vote BJ, Hall A, Cairns J, Buttery R. Changing trends in sympathetic ophthalmia. *Clin Experiment Ophthalmol* 2004;32:542–5.
- Jonas JB, Spandau UH. Repeated intravitreal triamcinolone acetonide for chronic sympathetic ophthalmia [letter]. *Acta Ophthalmol Scand* 2006;84:436.
- Chan RV, Seiff BD, Lincoff HA, Coleman DJ. Rapid recovery of sympathetic ophthalmia with treatment augmented by intravitreal steroids. *Retina* 2006;26:243–7.
- Jaffe GJ, Martin D, Callanan D, et al. Fluocinolone Acetonide Uveitis Study Group. Fluocinolone acetonide implant (Retisert for noninfectious posterior uveitis: thirty-four-week results of a multicenter randomized clinical study. *Ophthalmology* 2006;113:1020–7.
- Ramadan A, Nussenblatt RB. Visual prognosis and sympathetic ophthalmia. *Curr Opin Ophthalmol* 1996;7:39–45.
- Hakin KN, Pearson RV, Lightman SL. Sympathetic ophthalmia: visual results with modern immunosuppressive therapy. *Eye* 1992;6:453–5.
- Jennings T, Tessler HH. Twenty cases of sympathetic ophthalmia. *Br J Ophthalmol* 1989;73:140–5.
- Jaffe GJ, McCallum RM, Branchaud B, et al. Long-term follow-up results of a pilot trial of a fluocinolone acetonide implant to treat posterior uveitis. *Ophthalmology* 2005;112:1192–8.
- Callanan DG, Jaffe GJ, Martin DF, et al. Treatment of posterior uveitis with a fluocinolone acetonide implant: three-year clinical trial results. *Arch Ophthalmol* 2008;126:1191–201.
- Jaffe GJ. Reimplantation of a fluocinolone acetonide sustained drug delivery implant for chronic uveitis. *Am J Ophthalmol* 2008;145:667–75.
- Rao NA. Mechanisms of inflammatory response in sympathetic ophthalmia and VKH syndrome. *Eye* 1997;11:213–6.
- Chan CC, Roberge RG, Whitcup SM, Nussenblatt RB. 32 cases of sympathetic ophthalmia: a retrospective study at the National Eye Institute, Bethesda, Md., from 1982 to 1992. *Arch Ophthalmol* 1995;113:597–600.

## Footnotes and Financial Disclosures

Originally received: April 24, 2008.

Final revision: October 20, 2008.

Accepted: October 22, 2008.

Available online: January 14, 2009.

Manuscript no. 2008-509.

<sup>1</sup> Department of Ophthalmology and Visual Sciences, The University of Iowa Hospitals & Clinics, 200 Hawkins Drive, Iowa City, Iowa.

<sup>2</sup> Department of Ophthalmology and Visual Sciences, University of Illinois Eye and Ear Infirmary, Chicago, Illinois.

<sup>3</sup> Wills Eye Institute, Retina Service, Philadelphia, Pennsylvania.

<sup>4</sup> Sentro Oftalmogico Jose Rizal, University of the Philippines.

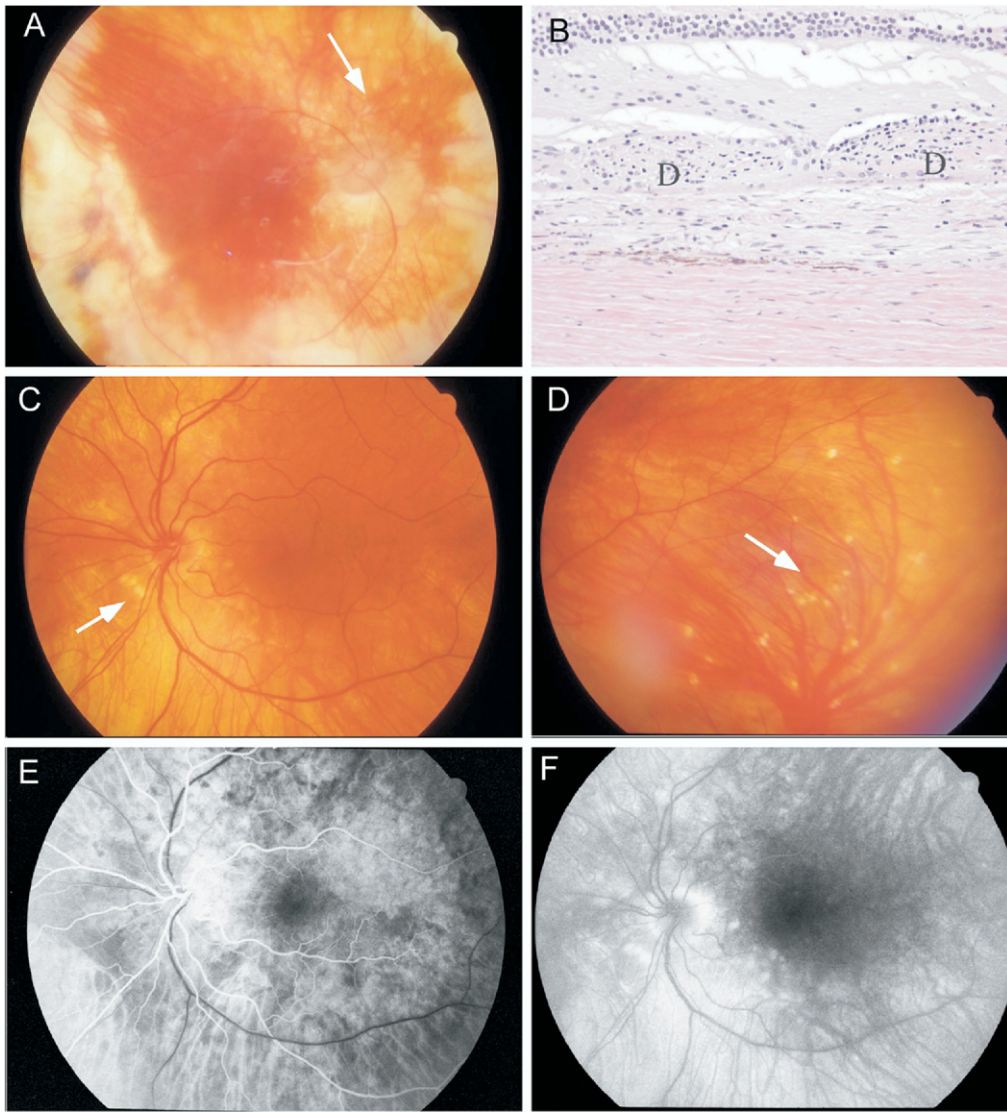
Dr. Folk received support for this study as the Judith (Gardner) and Donald H. Beisner, MD, Professor for Vitreoretinal Diseases and Surgery. Supported in part by an unrestricted grant from Research to Prevent Blindness, Inc., New York, New York.

Financial Disclosure(s):

The authors have no commercial or proprietary interests in any material discussed in this article.

Correspondence:

James C. Folk, MD, Department of Ophthalmology and Visual Sciences, The University of Iowa Hospitals and Clinics, 200 Hawkins Drive, Iowa City, IA, 52242. E-mail: james-folk@uiowa.edu.



**Figure 1.** Case 1. **A**, Fundus photo of the inciting eye with chorioretinal spots (arrow). **B**, Dalen-Fuch's nodules (D) are present in enucleation specimen. **C**, **D**, Sympathizing eye shows yellow chorioretinal spots (arrow). **E**, **F**, Early and late fluorescein angiograms show late leakage.