

Brief Report

Precision Medicine

Personalized Proteomics for the Diagnosis and Treatment of Idiopathic Inflammatory Disease

Gabriel Velez, BS; C. Nathaniel Roybal, MD, PhD; Diana Colgan, PhD; Stephen H. Tsang, MD, PhD; Alexander G. Bassuk, MD, PhD; Vinit B. Mahajan, MD, PhD

IMPORTANCE To better characterize posterior uveitis, vitreous samples from 15 patients were subjected to antibody arrays, and the expression levels of 200 human cytokines were evaluated. Expression was analyzed by 1-way analysis of variance (significance at $P < .01$), unsupervised cluster algorithm, and pathway analysis.

OBSERVATIONS Unbiased clustering of patients, based on their cytokine expression profile, suggested that particular protein networks and molecular pathways are altered in various forms of uveitis. Expression of interleukin 23 (IL-23), IL-1 receptor I (IL-1RI), IL-17R, tissue inhibitors of metalloproteinase 1 and 2 (TIMP-1 and TIMP-2), insulinlike growth factor-binding protein 2 (IGFBP-2), nerve growth factor (b-NGF), platelet-derived growth factor receptor β polypeptide (PDGFR β), bone morphogenic protein 4 (BMP-4), and stem cell factor (SCF) constituted a common cytokine signature in the vitreous of patients with uveitis. In 1 patient with progressive, idiopathic visual loss, this last-line analysis implicated retinal autoimmunity, a diagnosis that was validated when her serum sample was found to contain antibodies to S-arrestin, a retinal protein and potent cause of autoimmune retinal degeneration.

CONCLUSIONS AND RELEVANCE The analysis identifies a common cytokine signature for posterior uveitis and guides the diagnosis of a patient with idiopathic uveitis. Personalized treatment reversed the visual loss, illustrating how proteomic tools may individualize therapy.

JAMA Ophthalmol. doi:10.1001/jamaophthalmol.2015.5934
Published online February 4, 2016.

[+ Supplemental content at jamaophthalmology.com](#)

Author Affiliations: Author affiliations are listed at the end of this article.

Corresponding Author: Vinit B. Mahajan, MD, PhD, Department of Ophthalmology and Visual Sciences, University of Iowa Carver College of Medicine, 200 Hawkins Dr, Iowa City, IA 52242 (mahajanlab@gmail.com).

Inflammation of the retina and choroid (posterior uveitis) can be an early sign of systemic autoimmunity^{1,2}; until specific treatment can be initiated, immunologic attack progresses unabated. Inflammation is poorly tolerated by the neurosensory retina and can cause morbidity and irreversible blindness. The cause of most cases of posterior uveitis is undetermined because the different forms of the disease cannot be discriminated with clinical or current diagnostic biomarkers. Thus, cases of posterior uveitis are often labeled idiopathic¹ and are not addressed by specific treatments.

results of a complete blood cell count, erythrocyte sedimentation rate, and levels of C-reactive protein, antinuclear antibody, rheumatoid factor, interferon- γ release, HLA-B27, titers for Lyme disease, hepatitis B virus antibody, and hepatitis C surface antigen were within their reference ranges. Fluorescein angiographic and Goldmann visual field findings were unremarkable. Owing to the lack of conclusive findings, we labeled her condition an *idiopathic posterior uveitis*. Without a specific therapeutic protocol, we compared the cytokine profile of her vitreous biopsy findings with those of other uveitis cases to define her disease more precisely.

Report of a Case

We encountered a typical case of idiopathic uveitis (Figure 1). A woman in her 50s had poor vision, especially at night, but was otherwise healthy. Surgery removed an epiretinal membrane thought to cause her poor vision, but despite intermittent intravitreal corticosteroid injections, she experienced relapsing episodes of vitreous inflammation and retinal edema. Results of laboratory tests for posterior uveitis were normal;

Methods

We analyzed vitreous fluid biopsy findings from 15 patients with posterior uveitis and 5 control patients using a membrane-based, antibody array to monitor hundreds of cytokine-signaling molecules simultaneously (Figure 2 and eMethods in the Supplement). The patients included 3 with idiopathic posterior uveitis, 2 with intermediate uveitis, 4 with viral en-

dophthalmitis, 2 with autoimmune retinopathy, 1 with multifocal choroiditis, 1 with neovascular inflammatory vitreoretinopathy, and 1 with HLA-B27 uveitis (eTable 1 in the Supplement). We measured cytokine concentration and sorted the data into control and uveitis sections. Cytokine levels of 500 pg/mL or higher were evaluated further. Data were collected and analyzed from August 2011 to August 2015. The study was approved by the institutional review board of the University of Iowa and adhered to the tenets of the Declaration of Helsinki.³ All participants provided written informed consent.

Results

Unbiased cluster analysis identified 60 proteins as differentially expressed in uveitic vitreous ($P < .01$; eResults and eFigure 1A in the Supplement). In addition to the initial comparison, cases from each uveitis category were compared with controls and displayed characteristic expression profiles (eFigure 2 in the Supplement). Among these unique profiles, we detected a cytokine expression pattern (interleukin 23 [IL-23], IL-1 receptor I [IL-1RI], IL-17R, tissue inhibitors of metalloproteinase 1 and 2 [TIMP-1 and TIMP-2], insulinlike growth factor-binding protein 2 [IGFBP-2], nerve growth factor [b-NGF], platelet-derived growth factor receptor β polypeptide [PDGFR β], bone morphogenic protein 4 [BMP-4], and stem cell factor [SCF]) shared by all the patients with uveitis (eg, viral and autoimmune; Figure 2B and eTable 2 in the Supplement).

Like that of the other uveitis cases, our patient's vitreous contained 49 upregulated cytokine-signaling proteins; several were proinflammatory and previously linked to systemic inflammatory diseases (IL-1RI, CD40, CD40 ligand, major HLA-A, Fas, Fas ligand, T-cell IG mucin 1 [TIM-1], myeloid progenitor inhibitory factor 1, 4-1BB (also known as tumor necrosis factor receptor superfamily member 9 [TNFRSF9]), and triggering receptor expressed on myeloid cells 1 [TREM-1])⁴ and uveitis (IL-23 and IL-17).⁵ Many growth factors and receptors important for developing lymphocytes and clonal expansion were also upregulated (IL-2, IL-2R β , IL-17F, IL-17RI, B7-1, epidermal growth factor receptor [EGFR], PDGFR β , b-NGF, vascular endothelial growth factor receptor 3 [VEGF R3], placental growth factor [PIGF], mitochondrial substrate carrier family protein R [MCF R], galectin-7, endoglin, BMP-4, fibroblast growth factor 7 [FGF-7], resistin, insulinlike growth factor 1 [IGF-1], IGFBP-2, hemofiltrate CC-chemokine-1 [HCC-1], Tie-2, and SCF). Anti-inflammatory cytokines were also upregulated (IL-13RI, IL-10R β , lipocalin 2, and androgen receptor [AR]) (Figure 2A), consistent with the concept that anti-inflammatory cytokines balance immune responses.⁴ In addition, we detected soluble proteins known to attract lymphocytes to sites of inflammation, including macrophage inflammatory protein 1 (MIP), epithelial neutrophil-activating peptide 78 (ENA-78), cutaneous T-cell-attracting chemokine (CTACK), gamma-tubulin complex component 2 (GCP-2), thymus-expressed chemokine (TECK), intracellular adhesion molecule 3 (ICAM-3), epithelial cell adhesion molecule

Key Points

Question: Can proteomic profiles of cytokine expression in vitreous fluid biopsy diagnose an idiopathic case of uveitis?

Findings: In a patient with unexplained vision loss, vitreous cytokine expression profile was compared with profiles from a panel of uveitic abnormalities. The patient's cytokine profile implicated autoimmune retinopathy, resulting in the introduction of appropriate therapy, with sight retained in the left eye and saved in the right eye.

Meaning: Proteomic profiling of fluid biopsy samples may offer clinicians a new diagnostic tool.

(EpCAM), activated leukocyte cell adhesion molecule (ALCAM), and E-cadherin. The peptidase inhibitor proteins plasminogen activator inhibitor I (PAI-I), TIMP-1, and TIMP-2 were also upregulated (Figure 2A).⁴

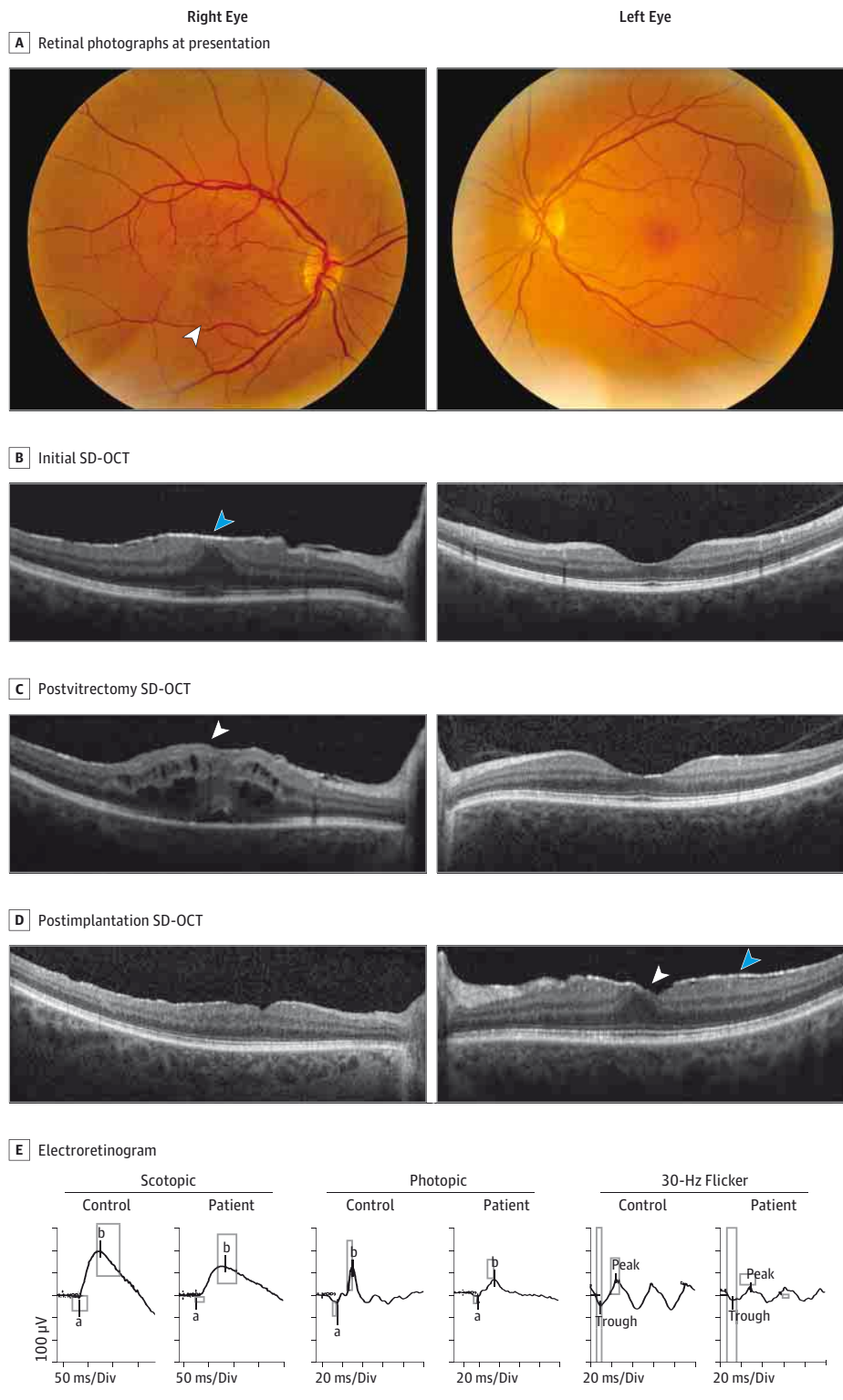The profile of our index patient (patient 9) clustered with the 2 cases of autoimmune retinopathy (Figure 2A) in which 17 cytokine signals were upregulated ($P < .01$) and 12 cytokines were downregulated (Figure 2C). Autoimmune retinopathy is caused by circulating antibodies to retinal proteins and typically causes bilateral visual loss, nyctalopia, and dyschromatopsia. Results of the examination can demonstrate retinal vascular attenuation, diffuse retinal atrophy, retinal pigment epithelial changes, and waxy disc pallor.⁶ Electroretinograms can detect abnormalities in rods, cones, or bipolar cell responses or a combination of these.⁶ At presentation, our patient had none of these typical findings; nevertheless, her personalized proteome data prompted us to test for antiretinal antibodies. Laboratory testing showed she was positive for antibodies against S-arrestin, a well-established cause of autoimmune uveitis.⁶

Based on this finding, we switched her treatment from intermittent injections of an immediate-release corticosteroid to surgical implantation of a controlled-release fluocinolone acetonide device (Retisert; Bausch & Lomb) that provided long-term, sustained intraocular immunosuppression. This treatment eliminated her retinal edema and improved her visual acuity from 20/70 to 20/30 OD. More than a year later, her originally asymptomatic left eye developed an epiretinal membrane with retinal edema (Figure 1D) and inflammatory precipitates typical of autoimmune retinopathy. Her electroretinogram also demonstrated a mildly decreased light-adapted and 30-Hz flicker (cone-specific) response, which was more pronounced in the left eye (Figure 1E). These later findings suggest the proteomic profile provided a correct diagnosis much earlier than conventional autoimmune retinopathy criteria.

Discussion

Patients with autoimmune-mediated inflammation pose diagnostic and therapeutic challenges because they often have nonspecific concerns and unremarkable examination findings, and their condition becomes classified as

Figure 1. Clinical Course of Idiopathic Inflammatory Eye Disease With Persistent Retinal Edema Before and After Personalized Proteomics

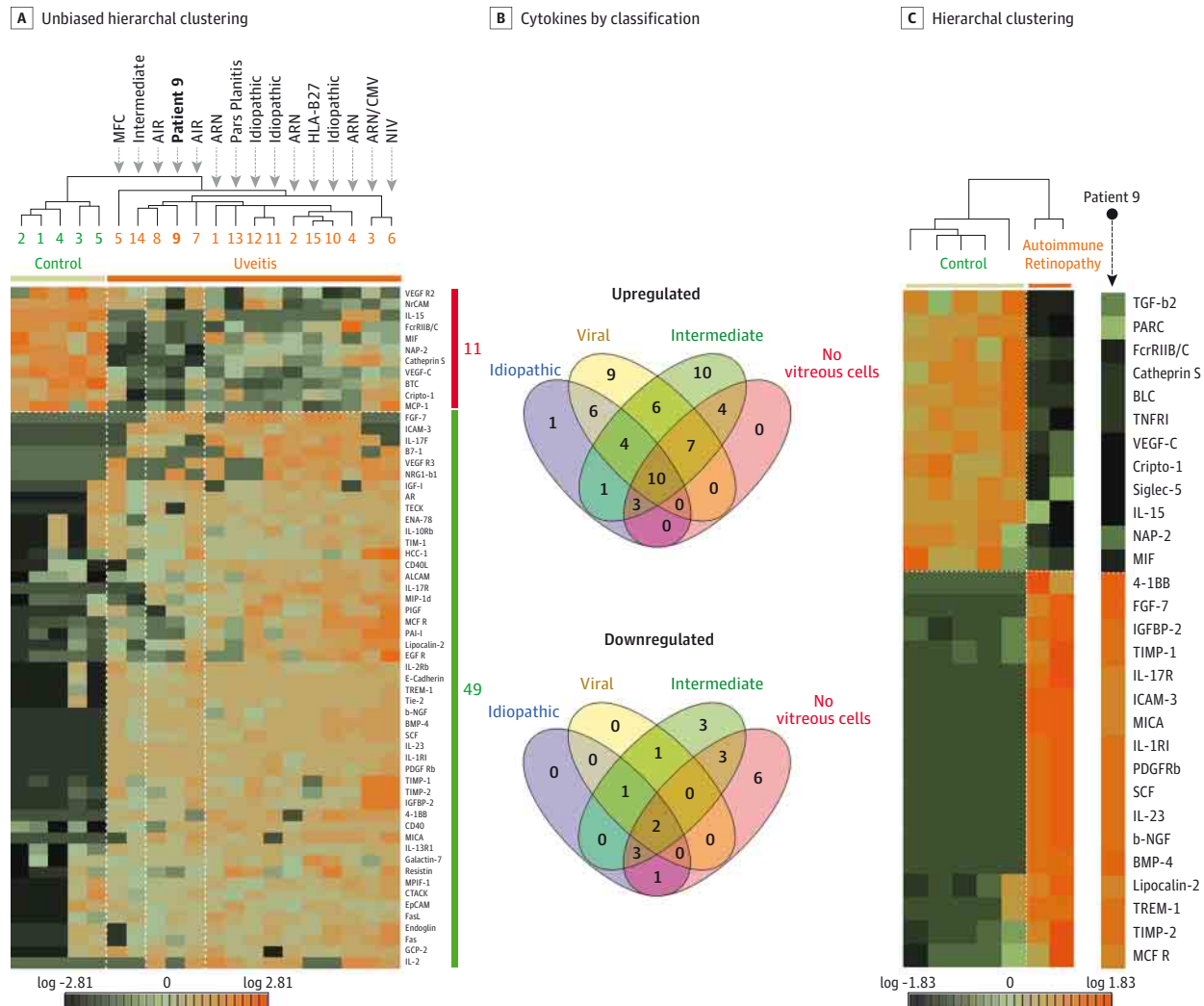


The patient had a visual acuity of 20/70 OD and 20/20 OS. A, Her right eye had an epiretinal membrane at presentation (white arrowhead); the left eye was normal. B, Spectral-domain optical coherence tomography (SD-OCT) confirmed the epiretinal membrane (blue arrowhead) and moderate cystic retinal edema in the right eye with a normal electroretinogram (ERG); the left eye had normal findings. C, The postvitrectomy SD-OCT showed relapsing retinal edema (white arrowhead) with 20/70 visual acuity OD, despite intermittent intravitreal corticosteroid injections, and normal findings in the postvitrectomy left eye. The personalized proteome of vitreous fluid biopsy indicated an antiretinal antibody autoimmune reaction (described in Figure 2). After implantation of a controlled-release fluocinolone acetonide device (Retisert; Bausch & Lomb), retinal edema resolved without any relapse, and her visual acuity stabilized to 20/30 OD. D, The left eye eventually developed retinal edema (white arrowhead) and an epiretinal membrane (blue arrowhead). E, The later ERG showed abnormalities consistent with retinal inflammation. The scotopic rod-specific ERG waveform was within a normal range. However, the transient photopic wave had a more than 3-ms delay in latency. In addition, the 30-Hz flicker was 50% below normal amplitudes with a 2-ms delay in latency. Div indicates division.

idiopathic. Diagnostic workups for inflammatory diseases can be prohibitively expensive and with a low yield of results. Proteomic profiling made a significant difference in our patient's case by guiding our diagnosis and therapeutic

choices. At an early disease stage, proteomic profiling directed laboratory testing to arrive at the correct diagnosis, which changed her treatment from intermittent corticosteroid injections (that allowed the corticosteroid concentra-

Figure 2. Common Cytokine Signature in a Vitreous Sample From a Patient With Idiopathic Inflammatory Eye Disease



A. Unbiased hierarchical clustering revealed the idiopathic inflammatory case (patient 9) clustered with cases of autoimmune retinopathy ($P < .01$). Orange indicates high expression; black to green, low expression, with black representing the lowest. B. Each uveitis type expressed unique protein profiles (described in eFigure 2 in the Supplement) and uveitis with a common cytokine signature consisting of upregulated interleukin 23 (IL-23), IL-1 receptor I (IL-1RI), IL-17R, tissue inhibitors of metalloproteinase 1 and 2 (TIMP-1 and TIMP-2), insulinlike growth factor-binding protein 2 (IGFBP-2), nerve growth factor (b-NGF), platelet-derived growth factor receptor β polypeptide (PDGFR β), bone morphogenic protein 4 (BMP-4), and stem cell factor (SCF) and downregulated vascular endothelial growth factor C (VEGF-C) and neutrophil-activating protein 2 (NAP-2). C. Hierarchical clustering of differentially expressed proteins ($P < .01$) show an unmistakable cytokine signature in the idiopathic case and autoimmune retinopathy cases. AIR indicates autoimmune retinopathy; ALCAM, activated leukocyte cell adhesion molecule; AR, androgen receptor; ARN, acute retinal necrosis; 4-1BB, tumor necrosis factor receptor superfamily member 9 (TNFRSF9); BLC, B lymphocyte chemoattractant;

BTC, betacellulin; CNV, choroidal neovascularization; CTACK, cutaneous T-cell-attracting chemokine; EGF R, endothelial growth factor receptor; ENA-78, epithelial neutrophil-activating peptide 78; EpCAM, epithelial cell adhesion molecule; FasL, Fas ligand; Fc γ RIIB/C, fragment crystallizable receptor II; FGF-7, fibroblast growth factor 7; GCP-2, granulocyte chemotactic peptide-2; HCC-1, hemofiltrate CC-chemokine-1; ICAM-3, intracellular adhesion molecule 3; IGF-1, insulinlike growth factor 1; MCF R, mitochondrial substrate carrier family protein; MCP-1, monocyte chemoattractant protein 1; MICA, major HLA-A; MIF, migration inhibitory factor; MIP-1d, macrophage inflammatory protein 1d; MIPF-1, myeloid progenitor inhibitory factor 1; MRC, macrophage mannose receptor 1; NrCAM, neuronal cell adhesion molecule; NRG1-b1, neuregulin-1; PAI-1, plasminogen activator inhibitor I; PARC, C-C motif chemokine 18; PlGF, placental growth factor; TECK, thymus expressed chemokine; TGF- β 2, transforming growth factor β 2; TIM-1, T-cell Ig mucin I; TNFR1, tumor necrosis factor receptor 1; and TREM-1, triggering receptor expressed on myeloid cells 1.

tion to wane and her disease to flare up) to a controlled-release device that lasts for 30 months.

Proteomic analysis of fluid biopsy results will likely become a new diagnostic and therapeutic approach for personalized medicine. Proteomics not only can identify biomarkers and potential drug targets but also provide insight into the

biological features driving the disease. In our case, we detected a cytokine signature—elevated levels of IL-23, IL-1RI, and IL-17R—that implicated autoimmune inflammation in our patient’s disease. Presumably, other fluid biopsy specimens from other sites affected by autoimmune diseases might have a similar cytokine signature or inflammatory biomarker.⁷⁻¹⁰ Our pa-

patient's elevated levels of PDGFR β and SCF (factors known to control remodeling of blood vessels) could point to molecular pathways driving the vascularization and edema that affected her retina.¹¹ Similarly, elevated TIMP-1 and TIMP-2 levels implicate matrix metalloproteinases.¹²⁻¹⁴ Other diseases that manifest with different symptoms in different organs might be driven by similar detectable biological processes.

Conclusions

Personalized proteomics for clinical analysis of fluid biopsy specimens open a new diagnostic and therapeutic approach for patient-specific therapies, a departure from generic treat-

ment or genetic testing.¹⁵ Protein expression is dynamic, correlating with disease timing, severity, and response to therapy. Armed with this approach, we might examine biopsy fluid samples from inflamed organs and identify key molecular constituents. Then, elevated immune effector levels can be targeted specifically, sometimes with existing drugs (eTable 3 in the Supplement). Because the vitreous does not normally contain cells, these abnormally expressed cytokines might be especially important clues for clinicians searching for effective treatment. Such an approach is likely to be applied to all types of disease eventually, but will be particularly important for patients with conditions such as autoimmune disease that begin with vague and variable symptoms but can cause rapid, irreversible deterioration if a correct diagnosis is delayed.

ARTICLE INFORMATION

Submitted for Publication: September 22, 2015; final revision received November 16, 2015; accepted December 5, 2015.

Published Online: February 4, 2016.
doi:10.1001/jamaophthalmol.2015.5934.

Author Affiliations: Omics Laboratory, University of Iowa Carver College of Medicine, Iowa City (Velez, Roybal, Colgan, Mahajan); Department of Ophthalmology and Visual Sciences, University of Iowa Carver College of Medicine, Iowa City (Velez, Roybal, Colgan, Mahajan); Medical Scientist Training Program, University of Iowa Carver College of Medicine, Iowa City (Velez); Barbara and Donald Jonas Laboratory of Stem Cells and Regenerative Medicine and Bernard and Shirlee Brown Glaucoma Laboratory, Edward S. Harkness Eye Institute, Columbia University, New York, New York (Tsang); Department of Pathology and Cell Biology, College of Physicians and Surgeons, Columbia University, New York, New York (Tsang); Department of Pediatrics, University of Iowa Carver College of Medicine, Iowa City (Bassuk).

Author Contributions: Dr Mahajan had full access to all the data in the study and takes responsibility for the integrity of the data and the accuracy of the data analysis.

Study concept and design: Roybal, Bassuk, Mahajan.
Acquisition, analysis, or interpretation of data: All authors.

Drafting of the manuscript: Velez, Roybal, Colgan, Bassuk, Mahajan.

Critical revision of the manuscript for important intellectual content: Roybal, Colgan, Tsang, Bassuk, Mahajan.

Statistical analysis: Velez, Bassuk.

Obtained funding: Mahajan.

Administrative, technical, and material support: Colgan, Tsang, Bassuk, Mahajan.

Study supervision: Bassuk, Mahajan.

Conflict of Interest Disclosures: All authors have completed and submitted the ICMJE Form for

Disclosure of Potential Conflicts of Interest and none were reported.

Funding/Support: This study was supported by grants K08EY020530 and R01EY016822 from the National Institutes of Health (Dr Mahajan), grant 2013103 from the Doris Duke Charitable Foundation (Dr Mahajan), Research to Prevent Blindness (Dr Mahajan), grant T32GM007337 from the National Institutes of Health (Mr Velez), and grants R01EY024698, R01EY018213, 5P30EY019007, and 5P30CA013696 from the National Institutes of Health (Barbara and Donald Jonas Laboratory of Stem Cells and Regenerative Medicine and Bernard and Shirlee Brown Glaucoma Laboratory).

Role of the Funder/Sponsor: The funding organizations had no role in design and conduct of the study; collection, management, analysis, and interpretation of the data; preparation, review, or approval of the manuscript; and decision to submit the manuscript for publication.

REFERENCES

- Guly CM, Forrester JV. Investigation and management of uveitis. *BMJ*. 2010;341:c4976.
- Chang JH, Wakefield D. Uveitis: a global perspective. *Ocul Immunol Inflamm*. 2002;10(4):263-279.
- World Medical Association. World Medical Association Declaration of Helsinki: ethical principles for medical research involving human subjects. *JAMA*. 2013;310(20):2191-2194. doi:10.1001/jama.2013.281053.
- Dinarelli CA. Historical insights into cytokines. *Eur J Immunol*. 2007;37(suppl 1):S34-S45.
- Ooi KG, Galatowicz G, Calder VL, Lightman SL. Cytokines and chemokines in uveitis: is there a correlation with clinical phenotype? *Clin Med Res*. 2006;4(4):294-309.
- Heckenlively JR, Ferreyra HA. Autoimmune retinopathy: a review and summary. *Semin Immunopathol*. 2008;30(2):127-134.
- Cretu D, Prassas I, Saraon P, et al. Identification of psoriatic arthritis mediators in synovial fluid by quantitative mass spectrometry. *Clin Proteomics*. 2014;11(1):27.
- Goo YA, Tsai YS, Liu AY, Goodlett DR, Yang CC. Urinary proteomics evaluation in interstitial cystitis/painful bladder syndrome: a pilot study. *Int Braz J Urol*. 2010;36:464-479.
- Wen H, Lee T, You S, et al. Urinary metabolite profiling combined with computational analysis predicts interstitial cystitis-associated candidate biomarkers. *J Proteome Res*. 2015;14(1):541-548.
- Kunz M, Ibrahim SM. Cytokines and cytokine profiles in human autoimmune diseases and animal models of autoimmunity. *Mediators Inflamm*. 2009;2009:979258.
- Carmeliet P, Jain RK. Molecular mechanisms and clinical applications of angiogenesis. *Nature*. 2011;473(7347):298-307.
- Hofmaier F, Hauck SM, Amann B, Degroote RL, Deeg CA. Changes in matrix metalloproteinase network in a spontaneous autoimmune uveitis model. *Invest Ophthalmol Vis Sci*. 2011;52(5):2314-2320.
- Romaniuk D, Kimsa MW, Strzalka-Mrozik B, et al. Gene expression of IGF1, IGF1R, and IGFBP3 in epiretinal membranes of patients with proliferative diabetic retinopathy: preliminary study. *Mediators Inflamm*. 2013;2013:986217.
- Casaroli-Marano RP, Pagan R, Vilaró S. Epithelial-mesenchymal transition in proliferative vitreoretinopathy: intermediate filament protein expression in retinal pigment epithelial cells. *Invest Ophthalmol Vis Sci*. 1999;40(9):2062-2072.
- Mahajan VB, Skeie JM. Translational vitreous proteomics. *Proteomics Clin Appl*. 2014;8(3-4):204-208.