

Original Investigation

Macular Hole Closure With Internal Limiting Membrane Abrasion Technique

Vinit B. Mahajan, MD, PhD; Eric K. Chin, MD; Ryan M. Tarantola, MD; David R. P. Almeida, MD, MBA, PhD; Riz Somani, MD; H. Culver Boldt, MD; James C. Folk, MD; Karen M. Gehrs, MD; Stephen R. Russell, MD

IMPORTANCE Internal limiting membrane (ILM) abrasion is an alternative surgical technique for successful full-thickness macular hole (MH) repair.

OBJECTIVE To study the effects of ILM abrasion as an alternative method of MH repair.

DESIGN, SETTING, AND PARTICIPANTS Retrospective consecutive case series from January 2006 to December 2008. Demographic data and preoperative, intraoperative, and postoperative examination records of all patients were reviewed for patients who underwent ILM abrasion with a diamond-dusted membrane scraper during vitrectomy for MH repair. A total of 100 eyes underwent ILM abrasion as an alternative to traditional ILM peeling.

MAIN OUTCOMES AND MEASURES Rate of MH closure and visual acuity (VA) outcomes at 3 months after surgery.

RESULTS Macular hole closure was achieved with a single surgical procedure in 94 of 100 eyes (94.0%; 95% CI, 87.4%-97.8%). Among all patients, the median preoperative VA was 20/100 (range, 20/30 to hand motions; 25th quartile, 20/60; and 75th quartile, 20/160), and the median postoperative VA at 3 months after surgery was 20/60 (range, 20/20 to hand motions; 25th quartile, 20/40; and 75th quartile, 20/100). Among all patients with stage 2 MHs, 30 of 38 patients (78.9%) had at least 2 lines of VA gain: 15 of 23 (65.2%) were phakic, and 15 of 15 (100%) were pseudophakic. Four of 38 patients (10.5%) with stage 2 MHs had at least 2 lines of VA loss, and all were phakic. Among all patients with stage 3 or 4 MHs, 42 of 62 (67.7%) had at least 2 lines of VA gain, of which 30 of 38 (78.9%) were phakic and 22 of 24 (91.7%) were pseudophakic. Six of 62 patients (9.7%) with stage 3 or 4 MHs had at least 2 lines of VA loss: 4 were phakic, and 2 were pseudophakic. In total, 35.0% (95% CI, 25.7%-44.3%) of patients achieved 20/40 vision or better, and 52.0% (95% CI, 42.2%-61.8%) of patients achieved 20/50 vision or better.

CONCLUSIONS AND RELEVANCE Abrasion of the ILM with a diamond-dusted membrane scraper at the time of vitrectomy achieves high rates of MH closure. This technique avoids complete removal of the retinal ILM basement membrane and subjacent tissues and appears to provide MH closure rates similar to those of traditional ILM peeling.

JAMA Ophthalmol. doi:10.1001/jamaophthalmol.2015.204
Published online March 12, 2015.

Author Affiliations: Department of Ophthalmology and Visual Sciences, University of Iowa Hospitals and Clinics, Iowa City (Mahajan, Chin, Almeida, Somani, Boldt, Folk, Gehrs, Russell); Omics Laboratory, University of Iowa, Iowa City (Mahajan); Saint Louis University Eye Institute, St Louis, Missouri (Tarantola).

Corresponding Author: Vinit B. Mahajan, MD, PhD, Department of Ophthalmology and Visual Sciences, University of Iowa Hospitals and Clinics, 200 Hawkins Dr, Iowa City, IA 52242 (mahajanlab@gmail.com).

Primary macular holes (MHs) are full-thickness neurosensory retinal defects of the fovea center, most commonly encountered in older women.^{1,2} An MH typically results in acute, moderate to severe visual loss.³ Evolving evidence from histology, ultrasonography, optical coherence tomography (OCT), posterior vitreous detachment association studies, and intraoperative anatomy supports the view that most MHs result from mechanical forces associated with residual posterior vitreous attachment.⁴⁻¹⁴ The residual posterior vitreous likely mediates anterior-posterior traction or tangential traction in the central fovea. Contributing to traction are contractile elements, including epiretinal membranes (ERMs), which are frequently identified on the retinal surface before surgery or at the time of MH repair.^{1,15-17} These contractile elements, whether extrinsic or intrinsic to the retina, or trauma may contribute to recurrent or reopening of MHs.¹⁸⁻²⁰ Although the exact mechanisms of successful repair are not completely understood, pars plana vitrectomy with gas injection and facedown positioning has proven to be highly successful at achieving MH closure and visual acuity (VA) improvement.²¹⁻²⁵ As surgical methods have improved and incorporated adjunctive enhancements such as long-acting gas tamponade, ERM peeling, and internal limiting membrane (ILM) peeling, reported MH closure rates have typically exceeded 90%.²⁶⁻³⁰

Various surgical techniques are used for peeling the ILM from the retinal surface. Most create a defect in the ILM, grasping an exposed edge with forceps and extending a circumferential tear around the MH. Alternatively, the ILM can be directly grasped with forceps and peeled from the retinal surface. We hypothesized that an alternative technique to address elements of tangential traction on the retinal surface may achieve similar MH closure rates without complete removal of the ILM. Furthermore, such a technique would limit the loss of subjacent tissue and reduce the risk of dye toxicity. A technique using a diamond-dusted membrane scraper (Tano DDMS; Synergetics Inc) to abrade the ILM was developed,³¹ and our experience is described herein.

Methods

Study Design

The operative reports, surgical logs, and medical records from a consecutive series of 100 patients with MHs at the University of Iowa who underwent surgical repair using an ILM abrasion technique described below were reviewed. The study dates were January 2006 to December 2008. Only patients who had at least 3 months of postoperative follow-up were included. Exclusion criteria were patients who had any ocular history of diabetic retinopathy, age-related macular degeneration, vascular occlusion, myopic degeneration, inflammatory disease, trauma, lamellar holes, chronic MH (present for >12 months, as confirmed by OCT), or previous MH repair using traditional ILM peeling techniques. Patients who had prior pars plana vitrectomy or decreased VA for any reason (eg, anterior segment disease, dense epiretinal membrane, etc) other than the MH were also excluded. The study protocol was ap-

proved by the Institutional Review Board for Human Subjects Research at the University of Iowa, and the study adheres to the tenets set forth in the Declaration of Helsinki. Informed consent was deemed not necessary for this retrospective study as per the university policy.

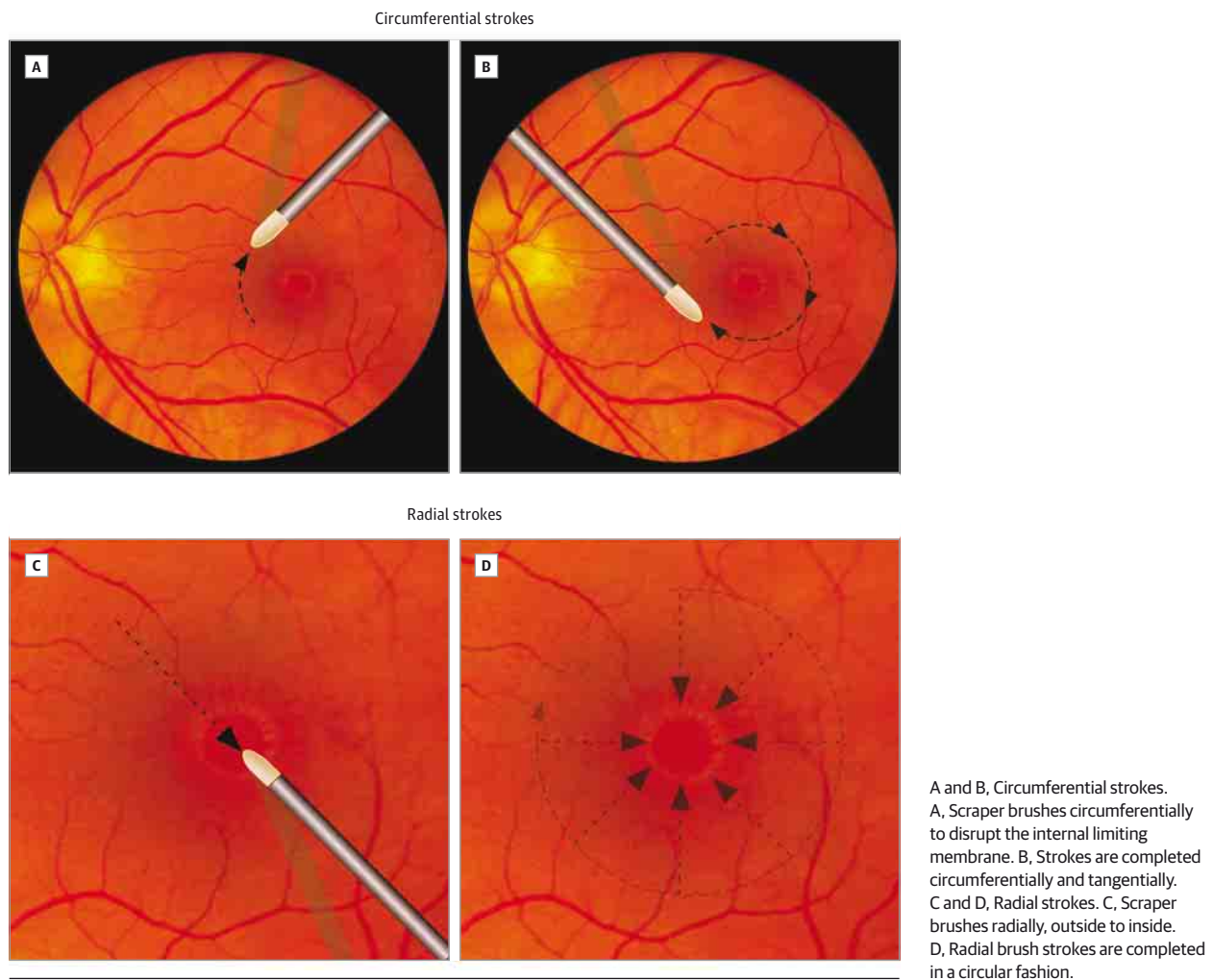
The MHs were staged by a modification of the classification by Gass³² by reviewing fundus images, OCT, medical record notes, and operative reports. Stage 2 MHs were defined as full-thickness retinal defects, less than 400 μm in diameter, without complete vitreous separation. Stage 3 and 4 MHs were defined as full-thickness retinal defects, 400 μm or greater in diameter, without and with complete posterior vitreous separation, respectively. This study did not review MH duration because these data were not available for all patients. Stage 1 MHs were not included in this study.

The primary study outcome evaluated was anatomic MH closure, confirmed by OCT, after a single surgical procedure. A secondary outcome was lines of VA improvement using a Snellen VA chart and the percentage of patients achieving VA improvement of 2 or more lines or 3 or more lines. Snellen VA was recorded in a clinical setting and represented the best VA measured. Refraction was not routinely performed, limiting the VA data in this retrospective study. The medians of preoperative and postoperative vision were calculated, as well as the 25th and 75th quartiles of VA. All patients underwent examination at postoperative day 1, week 1, month 1, and month 3. All eyes had a minimum follow-up duration of 3 months. For some eyes with longer than 3-month follow-up, subsequent examination data (ie, MH status, VA, and complications) were reviewed. The paired *t* test was used to compare VAs between the preoperative values and those obtained following surgery. The Fisher exact test was used to compare rates of closure between stage 2 MHs and stage 3 or 4 MHs. Statistical analysis, including calculation of the 95% CIs for binary percentages, was performed using a software program (SAS, version 9.1; SAS Institute Inc).

Surgical Technique

Three-port 20-gauge or 23-gauge pars plana vitrectomy was performed with retrobulbar anesthesia using monitored anesthesia care or general anesthesia. A caliper was used to mark the sclera 3 mm and 3.5 mm posterior to the limbus in pseudophakic and phakic eyes, respectively. The central vitreous was removed, and the vitrectomy was extended as close to the optic disc and posterior retina as judged safe by the surgeon (V.B.M., H.C.B., J.C.F., K.M.G., or S.R.R.). The posterior hyaloid was separated from the retinal surface by a suction using a silicone-tipped cannula or the vitreous cutter. The posterior vitreous detachment was extended around the optic nerve, across the macula, and into the midperiphery. Peripheral vitreous removal with the vitreous cutter and scleral depression were typically performed. At the surgeon's discretion, a dilute 50% solution of triamcinolone acetate was injected into the vitreous cavity to stain any remaining unopacified vitreous. Next, a diamond-dusted membrane scraper was brushed over the macula within an area of 1 disc diameter surrounding the MH. The diamond-dusted membrane scraper was gently angled, with its more rounded surface exposed along the

Figure 1. Diamond-Dusted Membrane Scraper Technique



tip's exterior angle. Brushing with the more rounded surface provides more uniform abrasions, less friction, and reduced risk of tearing tissue. When using the diamond-dusted membrane scraper with the interior angle toward the retina or when pushed toward its tip, abrasive force on the retina can be difficult to regulate, so this orientation was not used when brushing the ILM.

Two directional brush strokes were used. The first type of brush stroke was directed circumferentially around the MH (Figure 1A and B). We observed that this movement directs a force orthogonal to the traction lines of a presumed ERM or other contractile elements surrounding the MH. This orientation may help create greater and possibly safer vector forces to elevate a membrane and alleviate traction on the MH. The second type of brush stroke was oriented radially along meridional lines toward the MH (Figure 1C and D). Passing the diamond-dusted membrane scraper in a series of radial lines inward toward the MH and then across the MH edge was especially effective when a membrane was attached to the edge of the MH and inserted within the MH edge (Figure 2).

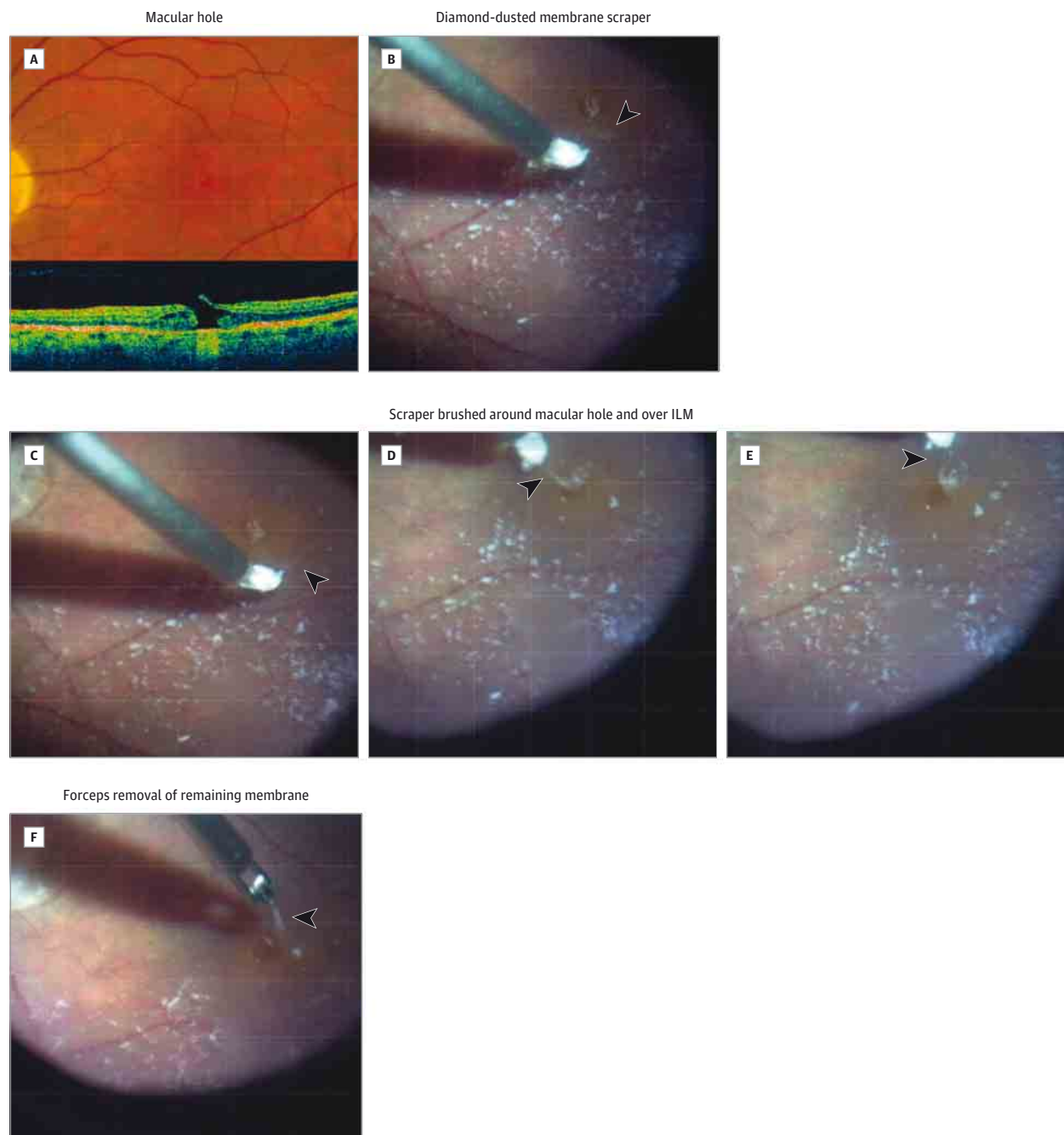
Occasionally, forceps were used to grasp and remove an elevated membrane with strong attachment to the MH edge

(Figure 2F). Repeat brush strokes over the ILM ensured removal of residual tissue without tearing or detaching the ILM from the retinal nerve fiber layer. Following an air-fluid exchange, a gas-air exchange was performed with 14% perfluoropropane or with 22% sulfur hexafluoride. Any sclerotomies that were not watertight at the conclusion of the case were closed with a single interrupted 7-0 polyglactin suture. Patients were instructed to assume a facedown position for 5 to 6 days after surgery.

Results

To determine the effectiveness of this technique in closing MHs, we reviewed 100 consecutive cases of pars plana vitrectomy with ILM abrasion. The mean (SD) patient age at the time of surgery was 69 (8) years (range, 42-90 years). Thirty-six patients were male, and 64 were female. There were 38 stage 2 MHs and 62 stage 3 or 4 MHs. Sixty-one patients were phakic, and 39 patients were pseudophakic. The postoperative follow-up interval ranged from 3 to 12 months.

Figure 2. Macular Hole Example



A, Color photograph and optical coherence tomography confirming a macular hole with vitreomacular traction. B, Diamond-dusted membrane scraper is pulled parallel to the macular hole (arrowhead), and a thin membrane elevates.

C-E, Diamond-dusted membrane scraper is brushed around the macular hole and radially over the internal limiting membrane (ILM) (arrowhead). F, Forceps removed the remaining membrane (arrowhead).

Macular hole closure was achieved with a single surgical procedure in 94 of 100 eyes (94.0%; 95% CI, 87.4%-97.8%). Among all patients with stage 2 MHs, 36 of 38 patients (94.7%; 95% CI, 82.3%-99.4%) achieved closure with a single surgical procedure. Among patients with stage 3 or 4 MHs, 58 of 62 patients (93.5%; 95% CI, 84.3%-98.2%) achieved closure with a single surgical procedure, and **no difference in closure rates between stage 2 MHs vs stage 3 or 4 MHs was identified**

($P > .99$). Persistent MHs were treated in 6 patients, all of which were closed following a second pars plana vitrectomy with traditional ILM peeling. No closed MHs reopened during postoperative follow-up.

The VAs in MHs closed following ILM abrasion were reviewed at 3 months; these measurements did not include updated manifest refractions. Among all patients, the median preoperative VA was 20/100 (range, 20/30 to hand motion; 25th

Table. Snellen Visual Acuity (VA) Outcomes Following Macular Hole Repair With Internal Limiting Membrane Abrasion Technique

Macular Hole Stage	Lens Status	Outcome					
		Median (25th to 75th Quartiles)		≥2 to <3 Lines of VA Gain	≥3 Lines of VA Gain	<2 Lines of VA Gain and <2 Lines of VA Loss	≥2 Lines of VA Loss
		Preoperative VA	3-Month Postoperative VA				
2	23 Phakic	20/80 (20/55 to 20/113)	20/50 (20/50 to 20/78)	7	8	4	4
	15 Pseudophakic	20/75 (20/53 to 20/100)	20/50 (20/30 to 20/100)	7	8	0	0
3 or 4	38 Phakic	20/100 (20/75 to 20/200)	20/50 (20/50 to 20/100)	9	21	4	4
	24 Pseudophakic	20/125 (20/80 to 20/200)	20/50 (20/40 to 20/120)	9	13	0	2

quartile, 20/60; and 75th quartile, 20/160), and the median postoperative VA at 3 months after surgery was 20/60 (range, 20/20 to hand motion; 25th quartile, 20/40; and 75th quartile, 20/100). Overall, 35.0% (95% CI, 25.7%-44.3%) of patients achieved 20/40 vision or better, and 52.0% (95% CI, 42.2%-61.8%) of patients achieved 20/50 vision or better.

Visual outcome (ie, gain, loss, or no change) was further subanalyzed based on the MH stage and lens status (Table). A total of 16 patients who were phakic had no change in VA or a loss of vision compared with only 2 patients who were pseudophakic. Unchanged or decreased VA was more prevalent among the phakic groups and was attributable to postoperative cataract progression. Patients with more advanced stages of MHs had worse median preoperative VA; however, the median postoperative VA at 3 months was the same (ie, 20/50) across all groups. Ophthalmoscopic examination and OCT demonstrated no posterior pole abnormalities in this group of eyes with more advanced stages of MHs (ie, stage 3 or 4). These patients returned to their referring ophthalmologist, with the expectation of improved VA following cataract removal and refraction. Follow-up data were not available to confirm improvement following cataract extraction. There were 2 pseudophakic eyes with stage 3 or 4 MHs that closed, with decreased postoperative VA. In one eye, a central retinal vein occlusion developed 2 weeks after surgery. In the other eye, subjective improvement of a long-standing central scotoma occurred, with a loss of VA of 1 line. There were 27 patients with 6-month follow-up data and 11 patients with 12-month follow-up data. During this extended follow-up period, none of these patients developed recurrent MHs, and none developed a loss of 2 or more lines of VA.

Finally, surgical complications were reviewed. Two patients developed a peripheral intraoperative rhegmatogenous retinal detachment. Both of these patients had successful retinal detachment repair, and their MHs remained closed. There were no cases of endophthalmitis. One patient developed a small and shallow suprachoroidal hemorrhage during surgery, which resolved spontaneously.

Discussion

The ILM is the basement membrane of the neurosensory retina and is developmentally deposited by Müller cells. On its in-

ner surface toward the vitreous, the ILM is contiguous with the posterior hyaloid. On its outer surface, the ILM is continuous with Müller cell end-feet and is variably adherent to the retinal nerve fiber layer and ganglion cell layer. Several groups have reported that removal of an annulus of ILM surrounding an MH increases closure rates compared with similar procedures without ILM removal.^{29,30,33} In addition, more recent data suggest that MHs may reopen at lower rates when the ILM is peeled.¹⁹ The ILM peeling is thought to ensure removal of residual cortical vitreous, ERMs, and vitreous-derived cells that may be left on the retinal surface. In addition, ILM peeling may activate Müller cells, stimulating the secretion of collagen, basement membrane components, and inflammatory factors. Together, these effects may stimulate glial-mediated closure of MHs and may explain the modestly higher closure rates observed with ILM peeling compared with vitrectomy and membrane peeling alone.³⁴

Data comparing MH closure rates and VA outcomes following pars plana vitrectomy with and without ILM peeling are not entirely consistent. A meta-analysis by Mester and Kuhn,³⁵ incorporating 1654 eyes from published data between 1992 to 1999, found that ILM peeling significantly improved anatomic closure rates from 77% to 96% and VA improvement of at least 2 lines from 55% to 81%, suggesting a significant benefit of ILM removal. In contrast, other investigations have not demonstrated significantly different postoperative visual results when comparing eyes that underwent ILM peeling with eyes that did not undergo peeling.³⁶ In 2006, Tognetto et al³⁷ published a multicenter review of 1627 eyes with MHs. They reported that ILM peeling significantly improved MH closure rates from 89.0% to 94.1%. However, there was no significant difference in closure rates for stage 2 MHs, and there were significantly higher closure rates in the ILM peeling group with stage 3 or 4 MHs. In that study, visual outcomes were similar between the groups with and without ILM peeling in MHs of all stages. In 2000, Margherio et al²⁷ reported no additional anatomic or visual benefit of ILM peeling compared with only inducing posterior vitreous detachment in stage 2 and 3 MHs. In addition, some patients with closed MHs following surgery may have inferior results when the ILM is removed. Al-Abdulla et al³³ found a statistically significant VA improvement of at least 3 lines at 3 months in 79.2% of 24 eyes with ERM removal only compared with 44.8% of 29 eyes with ERM and ILM removal. However, the final visual results were simi-

lar. Another study³⁸ found a delay in recovery of the focal macular electroretinographic b-wave after ILM removal, indicating alterations of the Müller cells that are involved in this electrophysiological response. This evidence has led some surgeons to reserve ILM peeling for stage 3 or 4 MHs, MHs that fail to close with initial surgery, or MHs that have reopened.

Further balancing the benefits of potentially higher MH closure rates with ILM peeling are risks associated with dyes used to visualize the ILM and the loss of retinal integrity and tissues coincident with ILM peeling. Some authors have advocated visualization of the ILM, facilitated by the use of dyes such as indocyanine green.³⁹ Accumulating evidence suggests that in some instances indocyanine green may be potentially toxic to the retina, resulting in reduced VA outcomes.³⁹ In the present retrospective study, indocyanine green staining was not used in any of 100 patients to eliminate this confounding variable and to potentially highlight an additional benefit of the ILM abrasion technique.

We report that 94.0% of eyes underwent successful surgical repair and closure of MHs using a single procedure with a novel technique. This may be comparable to reported rates of closure in investigations in which ILM peeling was performed.³⁷ In our study, the remaining 6.0% of eyes with persistently open MHs were closed with an additional procedure in which standard complete ILM peeling was performed. Our hypothesis is that in this subset of patients with unsuccessful

primary MH closure the ILM and membrane remained intact, and there was inadequate removal of the tractional forces. Alternatively, it is possible that patient positioning was insufficient or poorly compliant in this small cohort.

The limitations of our study are its retrospective nature and duration of variable follow-up. It is also limited by the lack of updated postoperative best-corrected VA with manifest refractions or lens status. However, our visual acuity outcome measures are similar to those of other studies^{28,35,37} using traditional ILM peeling techniques. We did not have a control group for comparison that underwent standard ILM peeling and it has been suggested that complete ILM peeling may ensure long-term closure rates.³⁷

Conclusions

In summary, we studied an alternative method of MH surgery that appears to preserve the intrinsic foveal tissues. Although our ophthalmology practice continues to perform complete ILM peels, the ILM abrasion technique seems to achieve similar closure rates and may be sufficient in early-stage MHs of short duration. Future long-term prospective randomized studies comparing ILM abrasion with ILM peeling, with inclusion of OCT and multifocal electroretinographic evaluations, will further compare these 2 surgical techniques for MH repair.

ARTICLE INFORMATION

Submitted for Publication: August 26, 2014; final revision received January 6, 2015; accepted January 9, 2015.

Published Online: March 12, 2015.
doi:10.1001/jamaophthalmol.2015.204.

Author Contributions: Dr Mahajan had full access to all the data in the study and takes responsibility for the integrity of the data and the accuracy of the data analysis.

Study concept and design: All authors.

Acquisition, analysis, or interpretation of data: All authors.

Drafting of the manuscript: All authors.

Critical revision of the manuscript for important intellectual content: All authors.

Administrative, technical, or material support: All authors.

Conflict of Interest Disclosures: All authors have completed and submitted the ICMJE Form for Disclosure of Potential Conflicts of Interest, and none were reported.

Funding/Support: Dr Mahajan is supported by grant KOBEYO20530 from the National Institutes of Health, by the Doris Duke Charitable Foundation, and by Research to Prevent Blindness.

Role of the Funder/Sponsor: The funding sources had no role in the design and conduct of the study; collection, management, analysis, and interpretation of the data; preparation, review, or approval of the manuscript; and decision to submit the manuscript for publication.

REFERENCES

- Gass JD. Idiopathic senile macular hole: its early stages and pathogenesis. *Arch Ophthalmol*. 1988;106(5):629-639.
- Gass JD. Risk of developing macular hole. *Arch Ophthalmol*. 1991;109(5):610-612.
- Casuso LA, Scott IU, Flynn HW Jr, et al. Long-term follow-up of unoperated macular holes. *Ophthalmology*. 2001;108(6):1150-1155.
- Johnson RN, Gass JD. Idiopathic macular holes: observations, stages of formation, and implications for surgical intervention. *Ophthalmology*. 1988;95(7):917-924.
- Gregor ZJ. Surgery for idiopathic full-thickness macular holes. *Eye (Lond)*. 1996;10(pt 6):685-690.
- Ezra E, Munro PM, Charteris DG, Aylward WG, Luthert PJ, Gregor ZJ. Macular hole opercula: ultrastructural features and clinicopathologic correlation. *Arch Ophthalmol*. 1997;115(11):1381-1387.
- Gass JD. Macular hole opercula: ultrastructural features and clinicopathologic correlation. *Arch Ophthalmol*. 1998;116(7):965-966.
- Campochiaro PA, Van Niel E, Vinos SA. Immunocytochemical labeling of cells in cortical vitreous from patients with premacular hole lesions. *Arch Ophthalmol*. 1992;110(3):371-377.
- Ezra E, Fariss RN, Possin DE, et al. Immunocytochemical characterization of macular hole opercula. *Arch Ophthalmol*. 2001;119(2):223-231.
- Hee MR, Puliafito CA, Wong C, et al. Optical coherence tomography of macular holes. *Ophthalmology*. 1995;102(5):748-756.
- Kusuhara S, Teraoka Escaño MF, Fujii S, et al. Prediction of postoperative visual outcome based on hole configuration by optical coherence tomography in eyes with idiopathic macular holes. *Am J Ophthalmol*. 2004;138(5):709-716.
- Tanner V, Chauhan DS, Jackson TL, Williamson TH. Optical coherence tomography of the vitreoretinal interface in macular hole formation. *Br J Ophthalmol*. 2001;85(9):1092-1097.
- Dugel PU, Smiddy WE, Byrne SF, Hughes JR, Gass JD. Macular hole syndromes: echographic findings with clinical correlation. *Ophthalmology*. 1994;101(5):815-821.
- Mackenzie SE, Gandorfer A, Rohleder M, et al. Ultrastructure and retinal imaging of internal limiting membrane: a clinicopathologic correlation of trypan blue stain in macular hole surgery. *Retina*. 2010;30(4):655-661.
- Azzolini C, Patelli F, Brancato R. Correlation between optical coherence tomography data and biomicroscopic interpretation of idiopathic macular hole. *Am J Ophthalmol*. 2001;132(3):348-355.
- Yoon HS, Brooks HL Jr, Capone A Jr, L'Hernault NL, Grossniklaus HE. Ultrastructural features of tissue removed during idiopathic macular hole surgery. *Am J Ophthalmol*. 1996;122(1):67-75.
- Avila MP, Jalkh AE, Murakami K, Trempe CL, Schepens CL. Biomicroscopic study of the vitreous in macular breaks. *Ophthalmology*. 1983;90(11):1277-1283.
- Johnson RN, McDonald HR, Lewis H, et al. Traumatic macular hole: observations, pathogenesis, and results of vitrectomy surgery. *Ophthalmology*. 2001;108(5):853-857.
- Kumagai K, Furukawa M, Ogino N, Larson E. Incidence and factors related to macular hole reopening. *Am J Ophthalmol*. 2010;149(1):127-132.

20. Yoshida M, Kishi S. Pathogenesis of macular hole recurrence and its prevention by internal limiting membrane peeling. *Retina*. 2007;27(2):169-173.
21. Kelly NE, Wendel RT. Vitreous surgery for idiopathic macular holes: results of a pilot study. *Arch Ophthalmol*. 1991;109(5):654-659.
22. Wendel RT, Patel AC, Kelly NE, Salzano TC, Wells JW, Novack GD. Vitreous surgery for macular holes. *Ophthalmology*. 1993;100(11):1671-1676.
23. Kim JW, Freeman WR, Azen SP, el-Haig W, Klein DJ, Bailey IL; Vitrectomy for Macular Hole Study Group. Prospective randomized trial of vitrectomy or observation for stage 2 macular holes. *Am J Ophthalmol*. 1996;121(6):605-614.
24. Freeman WR, Azen SP, Kim JW, el-Haig W, Mishell DR III, Bailey I; Vitrectomy for Treatment of Macular Hole Study Group. Vitrectomy for the treatment of full-thickness stage 3 or 4 macular holes: results of a multicentered randomized clinical trial [published correction appears in *Arch Ophthalmol*. 1997;115(5):636]. *Arch Ophthalmol*. 1997;115(1):11-21.
25. Smiddy WE, Pimentel S, Williams GA. Macular hole surgery without using adjunctive additives. *Ophthalmic Surg Lasers*. 1997;28(9):713-717.
26. Park DW, Sipperley JO, Sneed SR, Dugel PU, Jacobsen J. Macular hole surgery with internal-limiting membrane peeling and intravitreal air. *Ophthalmology*. 1999;106(7):1392-1397.
27. Margherio RR, Margherio AR, Williams GA, Chow DR, Banach MJ. Effect of perifoveal tissue dissection in the management of acute idiopathic full-thickness macular holes. *Arch Ophthalmol*. 2000;118(4):495-498.
28. Brooks HL Jr. Macular hole surgery with and without internal limiting membrane peeling. *Ophthalmology*. 2000;107(10):1939-1948.
29. Sheidow TG, Blinder KJ, Holekamp N, et al. Outcome results in macular hole surgery: an evaluation of internal limiting membrane peeling with and without indocyanine green. *Ophthalmology*. 2003;110(9):1697-1701.
30. Smiddy WE, Feuer W, Cordahi G. Internal limiting membrane peeling in macular hole surgery. *Ophthalmology*. 2001;108(8):1471-1476.
31. Lewis JM, Park I, Ohji M, Saito Y, Tano Y. Diamond-dusted silicone cannula for epiretinal membrane separation during vitreous surgery. *Am J Ophthalmol*. 1997;124(4):552-554.
32. Gass JD. Reappraisal of biomicroscopic classification of stages of development of a macular hole. *Am J Ophthalmol*. 1995;119(6):752-759.
33. Al-Abdulla NA, Thompson JT, Sjaarda RN. Results of macular hole surgery with and without epiretinal dissection or internal limiting membrane removal. *Ophthalmology*. 2004;111(1):142-149.
34. Nakamura T, Murata T, Hisatomi T, et al. Ultrastructure of the vitreoretinal interface following the removal of the internal limiting membrane using indocyanine green. *Curr Eye Res*. 2003;27(6):395-399.
35. Mester V, Kuhn F. Internal limiting membrane removal in the management of full-thickness macular holes. *Am J Ophthalmol*. 2000;129(6):769-777.
36. Bainbridge J, Herbert E, Gregor Z. Macular holes: vitreoretinal relationships and surgical approaches. *Eye (Lond)*. 2008;22(10):1301-1309.
37. Tognetto D, Grandin R, Sanguinetti G, et al; Macular Hole Surgery Study Group. Internal limiting membrane removal during macular hole surgery: results of a multicenter retrospective study. *Ophthalmology*. 2006;113(8):1401-1410.
38. Terasaki H, Miyake Y, Nomura R, et al. Focal macular ERGs in eyes after removal of macular ILM during macular hole surgery. *Invest Ophthalmol Vis Sci*. 2001;42(1):229-234.
39. Stanescu-Segall D, Jackson TL. Vital staining with indocyanine green: a review of the clinical and experimental studies relating to safety. *Eye (Lond)*. 2009;23(3):504-518.